

# Use of Ileum as Ureteral Replacement in Urological Reconstruction

Sandra A. Armatys, Matthew J. Mellon, Stephen D. W. Beck, Michael O. Koch, Richard S. Foster and Richard Bihrlé\*

From the Department of Urology, Indiana University School of Medicine, Indianapolis, Indiana

**Purpose:** We reviewed indications and outcomes in patients undergoing ileal ureter replacement for ureteral reconstruction.

**Materials and Methods:** Between December 1989 and September 2007, 105 patients underwent ileal ureter replacement, of whom 14 were excluded from study due to incomplete data. The remaining 91 patients (99 renal units) comprised the study cohort.

**Results:** Mean patient age was 46.8 years and mean followup was 36.0 months. Indications for an ileal ureter were stricture following genitourinary surgery in 29 cases (31.9%), radiation induced stricture in 17 (18.7%), nonurological surgery iatrogenic injury in 16 (17.6%) and retroperitoneal fibrosis in 11 (12.1%). Only 4 patients (4.4%) had primary ureteral cancer. Long-term complications included anastomotic stricture in 3 patients (3.3%) and fistula in 6 (6.6%). Serum creatinine decreased or remained stable in 68 patients (74.7%) and hyperchloremic metabolic acidosis developed in 3. No patient complained of excessive urinary mucous production.

**Conclusions:** In 68.1% of patients indications for an ileal ureter included radiation induced stricture or iatrogenic injury. The ileal ureter is a reasonable option for long-term ureteral reconstruction with preserved renal function in carefully selected patients.

**Key Words:** ureter, ileum, reconstructive surgical procedures, iatrogenic disease

SINCE its first description in 1906 by Shoemaker<sup>1</sup> and later popularization by Goodwin et al in the late 1950s,<sup>2</sup> the use of ileal segments for ureteral substitution has become a valuable procedure in reconstructive urology. Although it was initially described for tubercular obstruction, recent decades have seen the indications for its use broaden. We report a contemporary series representing changes in indications, patient selection and clinical outcomes.

## PATIENTS AND METHODS

### Study Design

After receiving institutional review board approval we retrospectively analyzed the records of all patients who underwent ileal ureter replacement at In-

diana University Medical Center from December 1989 through September 2007. Medical records were reviewed to include data on patient demographics, disease etiology, operative details, preoperative and postoperative complications, length of stay and followup.

### Followup

All patients underwent short-term followup with an outpatient clinic visit 3 to 4 weeks following hospital discharge. In addition, in those requiring long-term observation annual office visits were scheduled along with routine laboratory analysis and upper tract imaging.

### Surgical Technique

The techniques used for ileal ureter creation were similar to those described previously.<sup>3</sup> The length or location of injury

Submitted for publication April 18, 2008.  
Study received institutional review board approval.

\* Correspondence: Department of Urology, Indiana University School of Medicine, Indiana Cancer Pavilion, 535 North Barnhill Dr., Suite 420, Indianapolis, Indiana 46202 (telephone: 317-278-9300; FAX: 317-274-0174; e-mail: rbihrlé@iupui.edu).

For another article on a related topic see page 372.

precluded primary ureteroureterostomy, Boari flap or psoas hitch reconstruction, as judged by the managing surgeon. Ureteral substitution was performed with an isoperistaltic ileal segment in refluxing fashion unless otherwise described. Bilateral ureters were reimplanted into a common ileal segment in 8 patients using a segment of jejunum in 1 and a nipple valve, nonrefluxing distal anastomosis in 2. A transverse ileal segment from the right to the left kidney that was subsequently anastomosed to the bladder (7 configuration) was performed in 2 patients and a transverse ileal segment from the left to the right kidney that was subsequently anastomosed to the bladder (reverse 7 configuration) was performed in 4 (see figure).

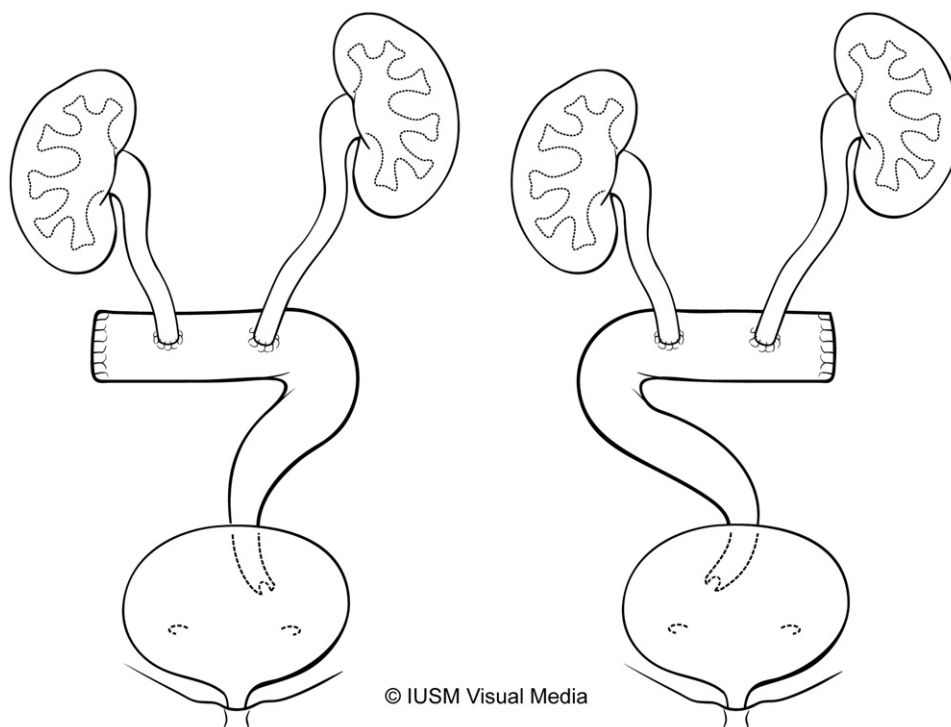
## RESULTS

The 91 patients had a mean age of 46.8 years (range 2 to 88) and were followed a mean of 36.0 months (range 6 to 159). A total of 99 renal units underwent ileal ureter replacement. The main indication for ureteral replacement in the current series was iatrogenic injury after urological procedures in 29 patients, including endoscopic ureterolithotomy or nephrolithotomy in 13, retroperitoneal lymph node dissection in 7, ureteral reimplantation in 3, ureteral avulsion in 4, anastomotic stricture following ileal loop and continent urinary reservoir urinary

diversion in 2, radiation induced stricture in 17 and iatrogenic injury involving a nonurological procedure in 16. Table 1 lists the remaining indications.

Ureteral obstruction developed in the proximal ureter in 14 renal units, the mid ureter in 24, the distal ureter in 36 and in 2 or more segments in 23. Of 83 patients 81 (97.6%) received a stent or percutaneous nephrostomy tube drainage before surgical intervention aside from intraoperative injuries, transitional cell carcinoma of the ureter and stone chute procedures. Only 63.7% of patients were stented postoperatively for an average of 11 days (range 2 to 48). The mean length of ileum used for interposition was 14.2 cm (range 4 to 35). For distal ureteral strictures the length of the stricture at surgery was judged by the surgeon to preclude Boari flap or psoas hitch reconstruction.

Median hospital stay was 7 days (range 3 to 66). Short-term complications (less than 30 days postoperatively) developed in 39 cases (42.9%). Table 2 lists these complications, classified according to the Clavien modified scale.<sup>4</sup> Many patients had multiple complications. One individual with multiple comorbidities received an ileal ureter for stricture following percutaneous nephrolithotomy. Postoperatively a severe wound infection developed, which led to wound dehiscence and subsequent sepsis. This re-



**Seven Configuration**

**Reverse-Seven Configuration**

**Table 1. Indications for ileal ureter**

	No. Pts
Urological surgery	29
Radiation fibrosis	17
Retroperitoneal fibrosis	11
Vascular surgery	8
Transitional cell Ca	5
Gynecological surgery	2
Tumor involving ureter	5
Stone chute	3
General surgery	2
Neurosurgery	2
Trauma	2
Amyloidosis	1
Idiopathic ureteral stricture	1
Congenital obstruction	1
Total	91

quired surgical repair and prolonged hospitalization for 2 months. The patient was eventually discharged home with stable renal function.

Table 3 lists long-term complications in nonirradiated and irradiated cases. Of note, anastomotic stricture developed in 3 patients (3.3%) and fistula developed in 6 (6.6%), requiring surgical repair. One patient had end stage renal disease secondary to recurrent obstructing transitional cell carcinoma in a solitary kidney. Two ipsilateral nephrectomies were performed. One patient experienced an iatro-

**Table 2. Short-term complications**

Clavien Grade <sup>4</sup> (complication)	No. Pts	
II:		
Urinary tract infection	14	
Prolonged ileus/partial small bowel obstruction	15	
Anastomotic bleeding requiring transfusion	1	
Ventriculoperitoneal shunt infection	1	
Atrial fibrillation	1	
Central venous line infection	2	
Wound infection	9	
Pancreatitis	2	
Hematuria requiring transfusion	2	
Deep venous thrombosis	2	
IIIa:		
Acute urinary retention	3	
Pneumothorax	1	
Pelvic abscess	1	
Decubitus ulceration	1	
Stent malfunction	7	
Iliac artery thrombosis	2	
Fascial dehiscence	2	
IIIb (pneumonia)		2
IVa:		
Respiratory failure, prolonged ventilation	2	
Myocardial infarction	1	
Acute renal failure	5	
Total*	76	

\* Many patients had multiple complications.

**Table 3. Long-term complications**

Clavien Grade <sup>4</sup> (complication)	No. Pts
<i>Radiation induced stricture disease (17 pts)</i>	
II:	
Recurrent urinary tract infections	2
Hyperchloremic metabolic acidosis	1
IIIb:	
Incisional hernia	1
Small bowel obstruction with adhesiolysis	3
Anastomotic stricture	1
Ileal ureteroenteric fistula	2
Enterovaginal fistula	2
IVa (ipsilat nephrectomy)	1
<i>Other indications (74 pts)</i>	
II:	
Femoral nerve palsy	1
Hyperchloremic metabolic acidosis	2
IIIb:	
Incisional hernia	3
Small bowel obstruction with adhesiolysis	1
Anastomotic stricture	2
Ileal ureterovaginal fistula	1
Enterocutaneous fistula	1
IVa:	
End stage renal disease	1
Short gut syndrome	1
Ipsilat nephrectomy	1

genic ileal ureter injury during sigmoid resection for diverticulitis and the other individual had progression to recurrent transitional cell carcinoma of the renal pelvis. No patients complained of excessive urinary mucous production and there were no deaths in the series.

Average preoperative and postoperative creatinine was 1.19 (range 0.4 to 2.4) and 1.28 mg/dl (range 0.4 to 7.9), respectively (p = 0.4881). Serum creatinine decreased or remained stable in 68 patients (74.7%) and 3 had hyperchloremic metabolic acidosis requiring oral sodium bicarbonate replacement (table 4). Six ureteral replacements were performed in patients with a baseline creatinine of greater than 2.0 mg/dl (mean 2.1, range 2.0 to 2.4).

**Table 4. Comparative renal function**

Postop Creatinine	No. Preop Creatinine (ng/dl)			Total No.
	0–0.9	1.0–1.9	2.0–2.9	
Ng/dl:				
0–0.9	18	11	0	
1.0–1.9	9	34	3	
2.0–2.9	0	9	1	
Greater than 3	0	2	0	
Not available	1	1	1	
Improved	Not available	11	3	14
Stable	18	34	2	54
Worsened	9	11	0	20
Not available	1	1	1	3
Totals	28	57	6	91

One patient had preoperative hyperchloremic metabolic acidosis and the remaining 5 had stable or improved renal function. Two patients had radiographic evidence of renal atrophy without hydronephrosis on the side of diversion but experienced no hypertension, change from preoperative creatinine or need for intervention.

## DISCUSSION

Many urologists rely on ureteral stents, percutaneous nephrostomy or nephrectomy in patients with chronic ureteral obstruction. Historically a review of 17 ileal ureter series with a total of 387 patients revealed that the most common indications were ureteral stricture following a urological procedure (22.0% of cases) and as a stone chute procedure for recurrent nephrolithiasis (16.5%) (table 5).<sup>1,5-20</sup> With the advent of better endoscopic techniques percutaneous nephrolithotomy and ureteroscopy have come to dominate management of ureteral calculi. Ureteral replacement has subsequently been performed less frequently. In fact, only 3 stone chutes were performed in our series after failed endourological management. Only within the last 2 decades have reports of ileal replacement for ureteral reconstruction become commonplace. The main advantage of reconstructing the ureter with ileum is the long-term avoidance of nephrostomy tubes, ureteral stents and nephrectomy. Furthermore, the ileal ureter requires no external devices, preserves renal function and has the advantage of using an uncompromised blood supply in irradiated cases.

If the selected patients have good renal function preoperatively, the risk of worsening uremia and hyperchloremic metabolic acidosis is low. Overall almost 75% of the patients in our series had improved or stable serum creatinine. Although glomer-

ular filtration rates would be an ideal assessment of renal function, we believe that serial creatinine values can provide insight into renal function with time. Furthermore, we caution against using an ileal ureter in patients with renal impairment preoperatively. Six patients in our series had a baseline preoperative creatinine of 2.0 mg/dl or greater. Although 5 of the 6 patients had subsequently improved or stable function, these individuals were carefully selected by the operating surgeon.

The short-term complication rate was 42.9% but overall long-term morbidity approximated 23%. We believe that this complication rate is attributable to the fact that 74 of 91 patients (81.3%) in our series underwent prior radiation therapy, endopyelotomy or open retroperitoneal surgery. Post-radiation cases had the highest rate of postoperative complications, such as wound infection, small bowel obstruction, ileus and fistula, which are part of the long-term difficulties associated with radiation induced fibrosis, ischemia and adhesive disease. In fact, 4 of the 6 patients in our series in whom enterovaginal, ureteroenteric or ureterovaginal fistulas developed had received radiation. All except 1 case of small bowel obstruction requiring adhesiolysis were in post-radiation cases. Despite the hostile environment of the post-radiated pelvis the small bowel is usually out of the radiation field and finding a suitable segment of ileum with good vascularity and length is technically feasible.

Our data correlate with those in previously published studies of ileum as a ureteral replacement in urological reconstruction. The largest series of ileal ureters to date was reported by Boxer et al from UCLA, which dates back to 1978 and documents reports of 94 ileal ureters in a total of 92 patients, spanning the 24 years from 1954 to 1978.<sup>9</sup> They found that 74.7% of 75 patients available for followup had stable or improved renal function. Importantly no patients with a preoperative creatinine of less than 2.0 mg/dl had problems with electrolytes postoperatively. Our stable or improved renal function rate of 74.7% correlates well with findings in that large series. This may reflect better preservation of renal function since 48.8% of their cases were performed as stone chutes and may have had normal nonobstructed kidneys before the procedure. The rate of hyperchloremic metabolic acidosis in other studies was 0% to 14%<sup>10,13,14,19</sup> compared to our 3.3% rate. With respect to postoperative complications McCullough et al reported that 58.3% of 12 patients had some complication, including anastomotic stenosis, mucous plugging, colocutaneous fistula, urine leak and worsening renal function in 1 each (8%).<sup>15</sup> In contrast, a review of 56 patients by Chung et al showed a 10% minor and 10.5% major postoperative complication rate.<sup>10</sup> Importantly only

**Table 5.** Historical indications for ileal ureter<sup>1,5-20</sup>

Indication	No. Pts (%)
Urological surgery	85 (22.0)
Stone chute/recurrent stones	64 (16.5)
Bilharzia	60 (15.5)
Radiation fibrosis	34 (8.8)
Gynecological surgery	33 (8.5)
Congenital obstruction	29 (7.5)
Miscellaneous	24 (6.2)
Retroperitoneal fibrosis	19 (4.9)
Transitional cell Ca	12 (3.1)
General surgery	9 (2.3)
Tuberculosis	6 (1.6)
Vascular surgery	6 (1.6)
Involved with malignancy	4 (1.0)
Interstitial cystitis	2 (0.5)
Trauma	1 (0.3)
Total	387

3 patients in this series received an ileal ureter due to post-radiation fibrosis.

Our series also reflects the change in indications for the ileal ureter with time. During an 18-year period we performed only 3 stone chutes in patients in whom endourological management of recurrent nephrolithiasis failed. With the advancement of ureteroscopic and percutaneous techniques the ileal ureter should be reserved as a last resort. Importantly in our contemporary series a large percent of ileal ureters was performed for radiation induced stricture disease (19.2%). To our knowledge we are the first to report a large cohort of post-radiation patients and evaluate clinical outcomes in this subset. Unfortunately the complication rates reflect this complicated subset of patients.

## CONCLUSIONS

Ileal ureter replacement is a technically feasible surgery to be performed in any patient requiring ureteral reconstruction despite a normal contralateral kidney. As such, it is a better alternative than nephrectomy in cases of complex and multiple ureteral strictures. It portends good long-term results for the relief of obstructive uropathy and the preservation of renal function. The associated complications and morbidity of ureteral replacement should be considered in patient selection. The long-term benefits should compare favorably to short-term morbidity. A half century later the ileal ureter remains an excellent solution for an obstructed ureter when other reconstructive measures from within the urinary tract are judged to be impossible.

## REFERENCES

1. Shoemaker J: Discussie op voordracht van J. M. van Dam over interabdominale plastiken. *Ned Tijdschr Geneesk* 1911; p 836.
2. Goodwin WE, Winter CC and Turner RD: Replacement of the ureter by small intestine: clinical application and results of the ileal ureter. *J Urol* 1959; **81**: 406.
3. Goodwin WE and Cockett AT: Surgical treatment of multiple, recurrent, branched, renal (staghorn) calculi by pyelonephro-ileo-vesical anastomosis. *J Urol* 1961; **85**: 214.
4. Dindo D, Demartines N and Clavien PA: Classification of surgical complications: a new proposal with evaluation in a cohort of 6336 patients and results of a survey. *Ann Surg* 2004; **240**: 205.
5. Abrams HJ and Neier CR: Ureteral substitution with ileum. *Am Surg* 1967; **33**: 437.
6. Amin HA: Experience with the ileal ureter. *Br J Urol* 1976; **48**: 19.
7. Benson MC, Ring KS and Olsson CA: Ureteral reconstruction and bypass: experience with ileal interposition, the Boari flap-psoas hitch and renal autotransplantation. *J Urol* 1990; **143**: 20.
8. Bonfig R, Gerharz EW and Riedmiller H: Ileal ureteric replacement in complex reconstruction of the urinary tract. *BJU Int* 2004; **93**: 575.
9. Boxer RJ, Fritzsche P, Skinner DG, Kaufman JJ, Belt E, Smith RB and Goodwin WE: Replacement of the ureter by small intestine: clinical application and results of the ileal ureter in 89 patients. *J Urol* 1979; **121**: 728.
10. Chung BI, Hamawy KJ, Zinman LN and Libertino JA: The use of bowel for ureteral replacement for complex ureteral reconstruction: long-term results. *J Urol* 2006; **175**: 179.
11. Dowd JB and Chen F: Ileal replacement of the ureter in solitary kidney. *Surg Clin North Am* 1971; **51**: 739.
12. Ghoneim MA and Shoukry I: The use of ileum for correction of advanced or complicated bilharzial lesions of the urinary tract. *Int Urol Nephrol* 1972; **4**: 25.
13. Kvarstein B and Mathisen W: Total replacement of ureter with a segment of ileum. *Scand J Urol Nephrol* 1977; **11**: 249.
14. Matlaga BR, Shah OD, Hart LJ and Assimos DG: Ileal ureter substitution: a contemporary series. *Urology* 2003; **62**: 998.
15. McCullough DL, McLaughlin AP, Gittes RF and Kerr WS Jr: Replacement of the damaged or neoplastic ureter by ileum. *J Urol* 1977; **118**: 375.
16. Prout GR Jr, Stuart WT and Witus WS: Utilization of ileal segments to substitute for extensive ureteral loss. *J Urol* 1963; **90**: 541.
17. Schoeneich G, Winter P, Albers P, Frohlich G and Muller SC: Management of complete ureteral replacement. Experiences and review of the literature. *Scand J Urol Nephrol* 1997; **31**: 383.
18. Shokeir AA and Ghoneim MA: Further experience with the modified ileal ureter. *J Urol* 1995; **154**: 45.
19. Verduyck FJ, Heesakkers JP and Debruyne FM: Long-term results of ileum interposition for ureteral obstruction. *Eur Urol* 2002; **42**: 181.
20. Waldner M, Hertle L and Roth S: Ileal ureteral substitution in reconstructive urological surgery: is an antireflux procedure necessary? *J Urol* 1999; **162**: 323.